

www.ankle-arthroscopy.co.uk

Ankle Arthroscopy

[HOME](#) [PATIENTS' SITE](#) [SURGEONS' SITE](#) [VIDEOS](#) [ABOUT SIMON MOYES](#) [CONTACT](#) [LINKS](#)



Ankle Arthroscopy Website

Simon Moyes specialises in keyhole – or arthroscopic – surgery. This site is dedicated to conditions of the ankle joint that are treated by Simon. Patients can find all the information they need about some of the more common ankle problems, while surgeons and medical professionals can find an up-to-date medical resource for those involved in or studying ankle arthroscopy.

Quick Search

Go straight to the specific page you are looking for by using the drop down below:

Specific Condition

Search Site

Patients' Site

An outline of common ankle problems, with information about how the injury / ailment feels, what surgery is likely and the projected recovery time.

[Click here for the Patients' Site](#)

Surgeons' Site

An in-depth resource about all aspects of ankle arthroscopy for medical professionals. Contains highly-referenced documentation of the procedure, citing examples from the early history to current findings.

[Click here for the Surgeons' Site](#)

Simon Moyes | Medico-legal © Simon Moyes 2007 | sitemap | disclaimer

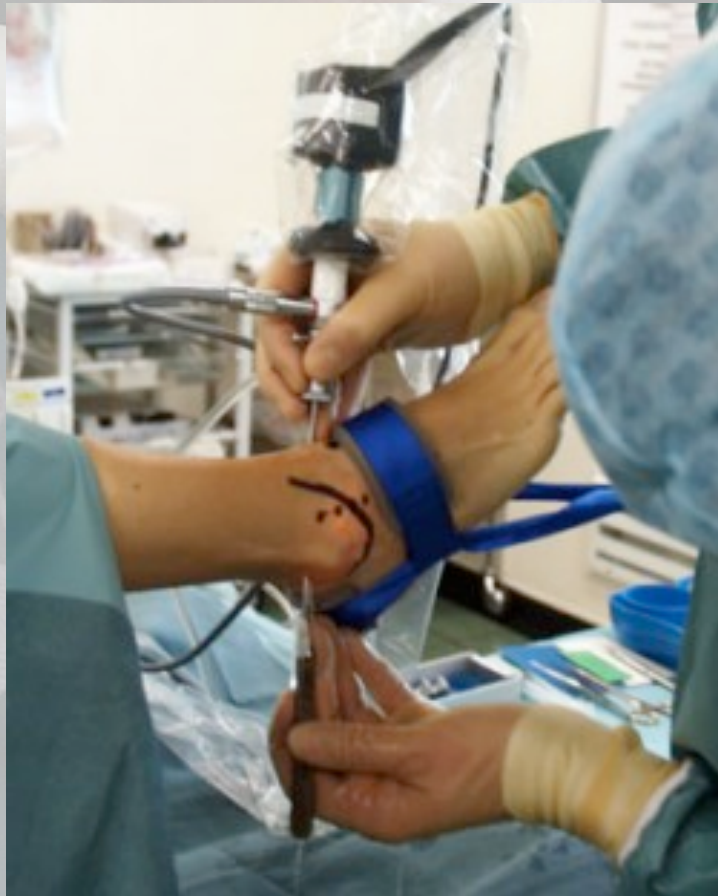oscopy.co.uk

A close-up photograph of a hand in a white surgical glove holding a patient's foot. The foot is positioned on a white surface, likely a table or tray. The background is dark and out of focus. The text is overlaid on the image.

Ankle Arthroscopy and post traumatic pain.

Presented by Mr Simon Moyes

Diagnostic Examination

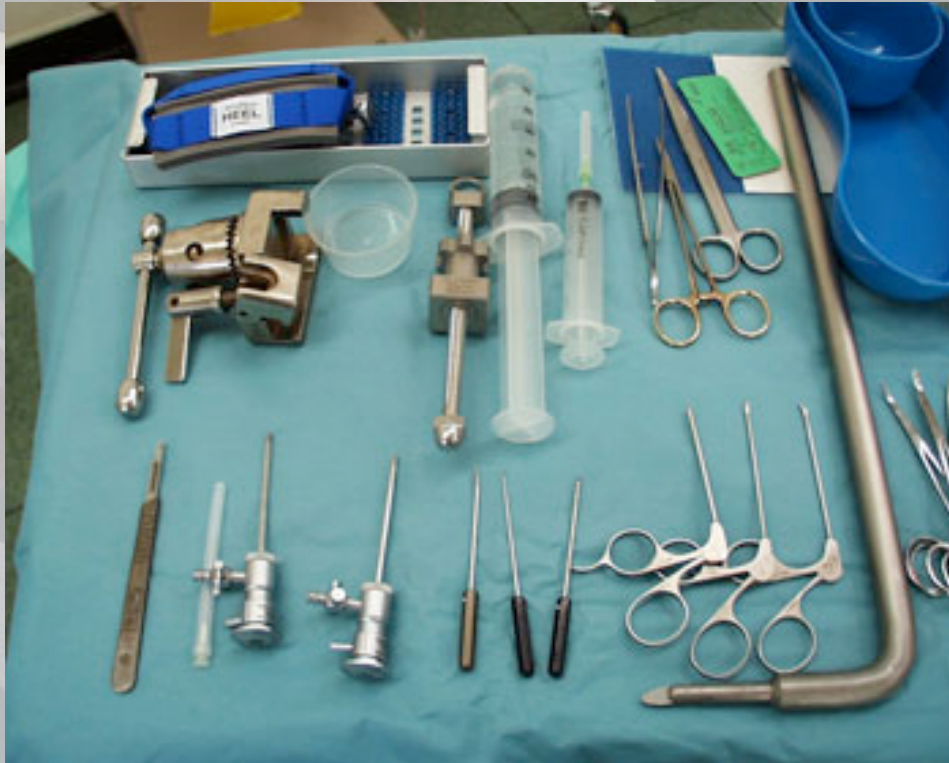

The ankle is first distended with approx 30cc of saline.

- The anteromedial portal is established just medial to tibialis anterior at the level of the joint line carefully avoiding the saphenous nerve.
- Then the anterolateral portal is established using transillumination, avoiding the superficial branch of the lateral popliteal nerve. A full diagnostic inspection of the anterior compartment is then carried out.
- Then the posterolateral portal is made, localising the entry point with a spinal needle. A full inspection of the posterior compartment is then made.

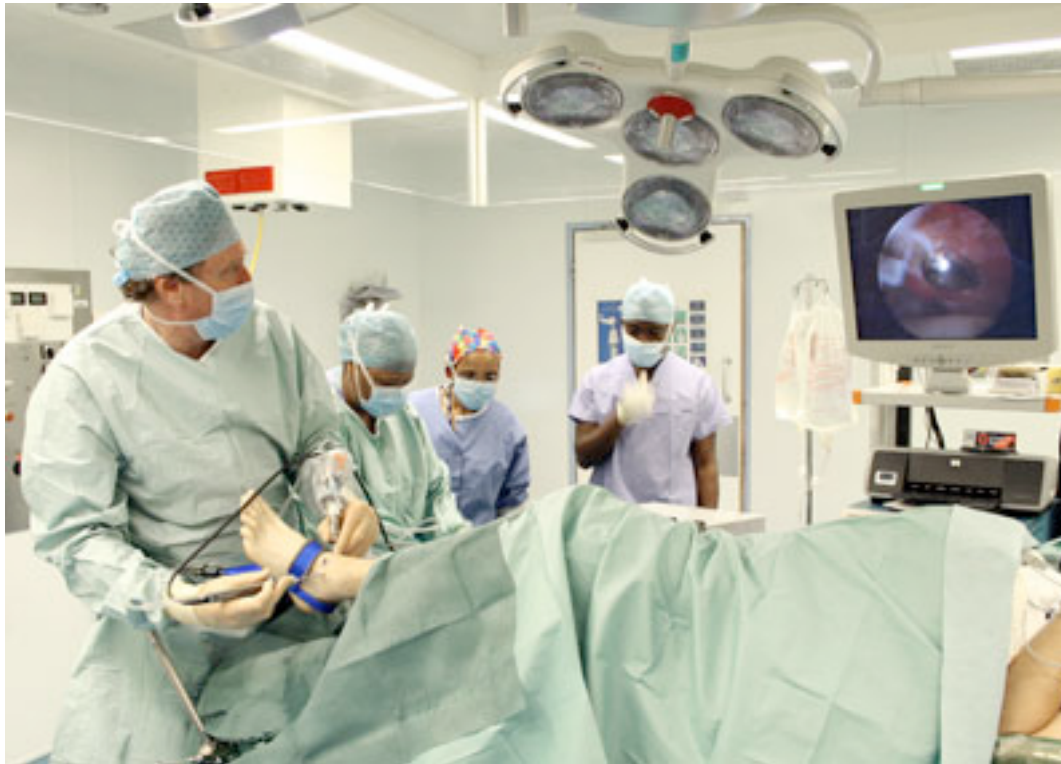Using these three portals, a full systematic ankle examination can be carried out.

Instrumentation



- Instrumentation Spinal needles
- Probes
- Dissectors - elevating OCD lesions, ossicles
- Graspers - flat-tipped or pitbull for small or large loose bodies (2.7 - 3.0mm)
- Basket forceps - straight, right and left, up and down angles (2.5 - 3.0mm)
- Knives
- Curettes
- Osteotomes
- Power instruments
- Thigh/Ankle holder
- Aiming jigs

Theatre Set-Up

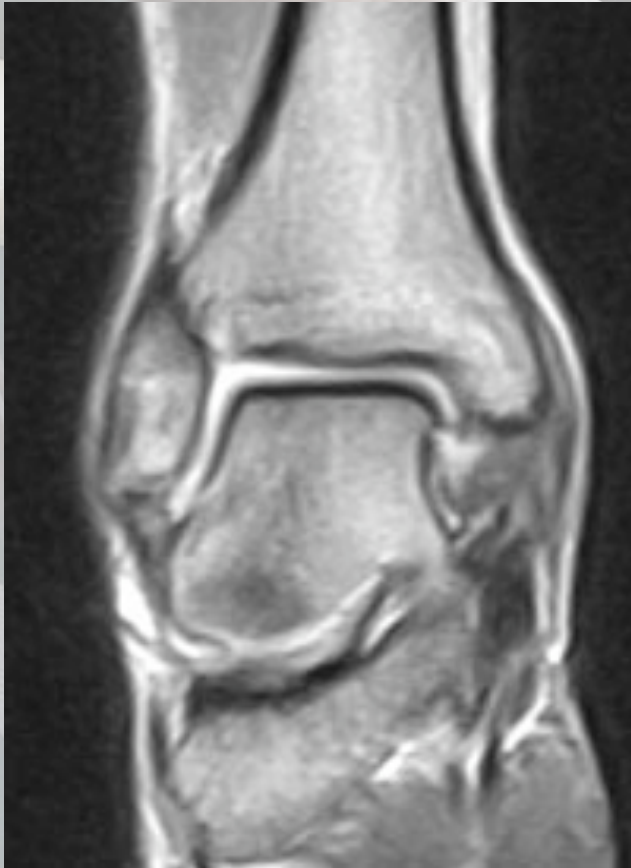

- Posterolateral Irrigation
- Large Joint Shavers
- Image Intensifier
- Large Fragment AO Cannulated Screws

Soft Tissue Lesions

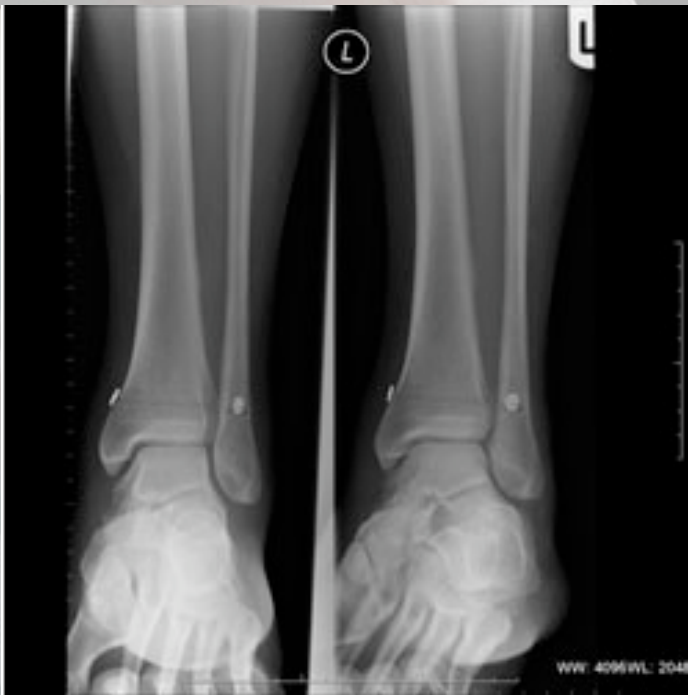- Patients with such lesions present with a combination of pain, swelling, tenderness, locking and giving way.
- On examination, one finds a combination of tenderness, wasting, swelling, restricted range and instability.
- Investigations include XR, CT, MRI, arthritis tests. These all may be negative.
- Classification
 - Congenital: plicae / bands
 - Excise
 - Traumatic: sprains, fractures, prior surgery
 - Excise generalised synovitis
 - Excise localised bands
 - Excise meniscoid lesions secondary to impingement

Arthrofibrosis



- Lateral ligament injuries are very common, with 1 ankle sprain per 10,000 occurring per day (8). Some 10-50% have some chronic pain (9,10,11).
- Anterolateral impingement is the commonest soft tissue impingement lesion and cause of pain after ankle inversion injury (12). Wolin coined the term 'the meniscoid lesion' for the arthroscopic appearance of the lateral gutter in these patients.
- Arthroscopic treatment is very successful in alleviating chronic pain (13,14,15,16) in 84% both subjectively and objectively. A recent survey by Urg'den M et al (17) in 2005 of 41 patients showed good or excellent results in 37 of the group. Also Henderson et al in 2004 showed similar results for combined anterior and posterior impingement syndrome (18).
- During dorsiflexion of the ankle, the malleoli are separated and the syndesmosis is stressed. Syndesmotic injuries are undoubtedly underestimated (19). Syndesmotic injuries can be diagnosed by a localised tenderness and a positive squeeze test (20, 21) - pressing the tibia and fibula together to compress the syndesmosis.

Impingement Lesions



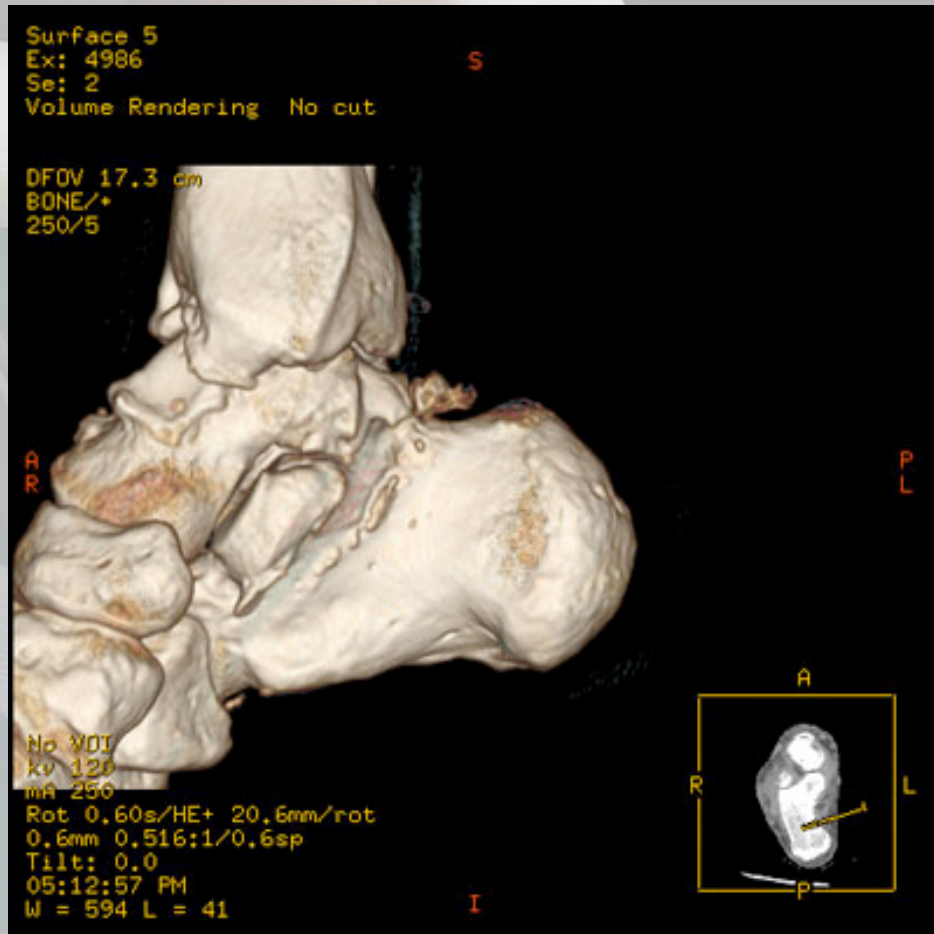
- Arthrofibrosis post fracture or sprain can occur and is satisfactorily treated by arthroscopic resection of the fibrous bands and early physiotherapy.

This was nicely demonstrated by Lui T H et al in 2006 (35)

Inflammatory Lesions

- Rheumatoid arthritis, X-tal synovitis, PVNS and synovial chondromatosis can all affect the ankle.
- Rheumatoid arthritis has been reported to have an arthroscopic cure (26). A 95% synovectomy is possible (27), and early synovectomy is better than late (28).
- PVNS can be treated arthroscopically in the ankle as elsewhere (29).
- Synovial chondromatosis is rare in the ankle, but is treated along standard arthroscopic lines (30).
- Other arthritides such as gonarthritides, Crohn's, gout, chondrocalcinosis are treated with arthroscopic synovectomy (31).
- An article in 2004 in the Journal of Paediatric Orthopaedics (32) of 39 ankles shows successful results with arthroscopic synovectomy for haemophilic arthropathy.

Articular Surface Defects

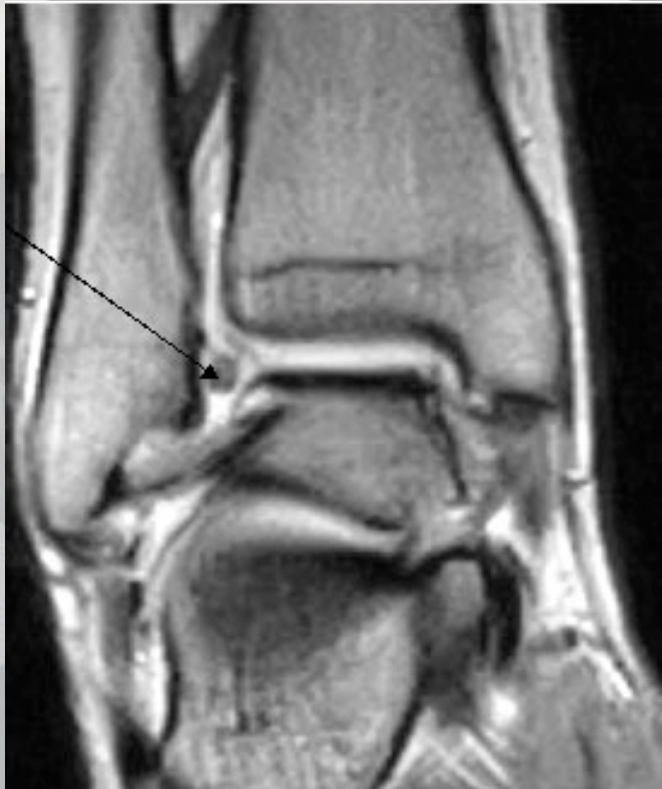

- Arthroscopy is the best way of visualising and treating articular surface defects.

Chondral Lesions

- Chondral lesions are usually caused by a sprain or by an RTA with direct compression of the articular cartilage. The pathologies range from blistering to full thickness flap tears. These lesions are frequently missed because of normal XR in A/E. If such lesions are suspected, then ankle arthroscopy is the only sure way to diagnose them with a full examination of anterior and posterior compartments required.
- Arthroscopic surgery is straightforward resecting chondral flaps to stable base and drill exposed bone (85) to encourage vascular invasion and fibrocartilage formation.
- Ankle arthroscopic debridement and lavage parallels that of arthroscopic treatment of DJD in other joints (86).

Loose Bodies

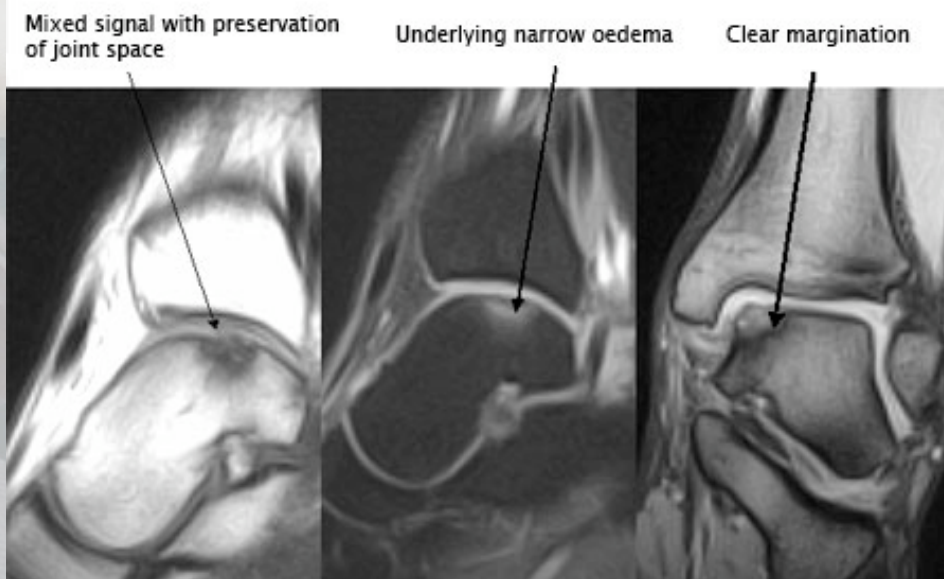


- Primary and secondary osteoarthritis can be treated arthroscopically.
- Cheng and Ferkel (87) in 1998 showed that arthroscopic debridement for ankle and subtalar degenerative disease can provide an interim alternative to arthrodesis or ankle replacement, with removal of impinging osteophytes and loose bodies being treated effectively with arthroscopy.

Osteophytes

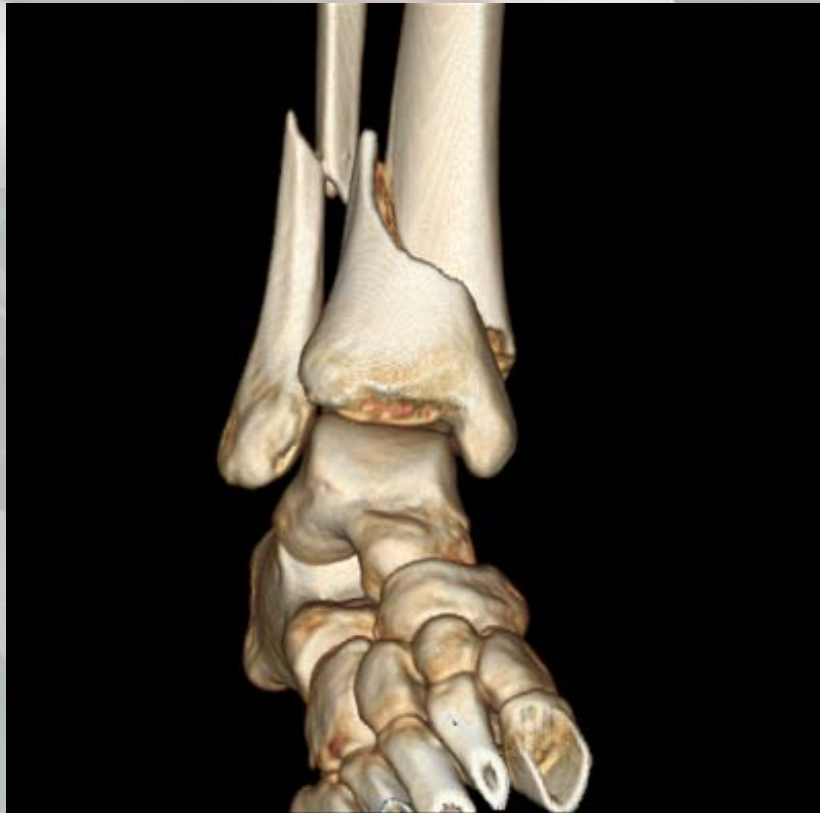- Pre Op 3-D CT Takao M et al, 2004
- 77% good or excellent results with Grade 1 disease
- Plain lateral X-Ray insufficient

Osteochondral Lesions of the Talus - OLT



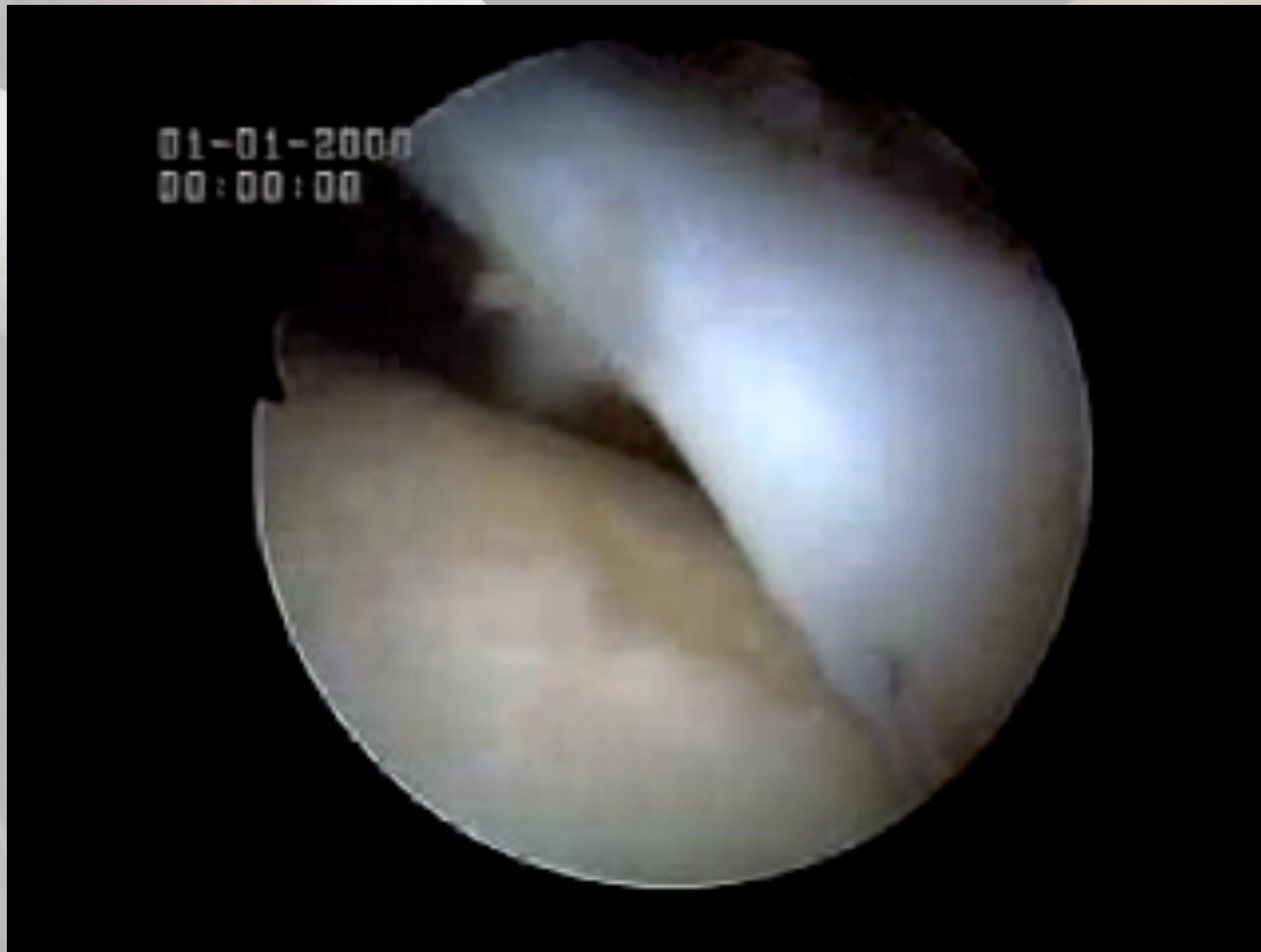- Osteochondral lesions of the talus as such were first described in 1856 by Monroe (36) but Konig (37) coined the term 'osteochondritis' when he found similar pathology elsewhere in the body and thought the aetiology was osteonecrosis. Kappis (38) in 1922 first applied the term osteochondritis to the ankle joint.

Ankle Fractures

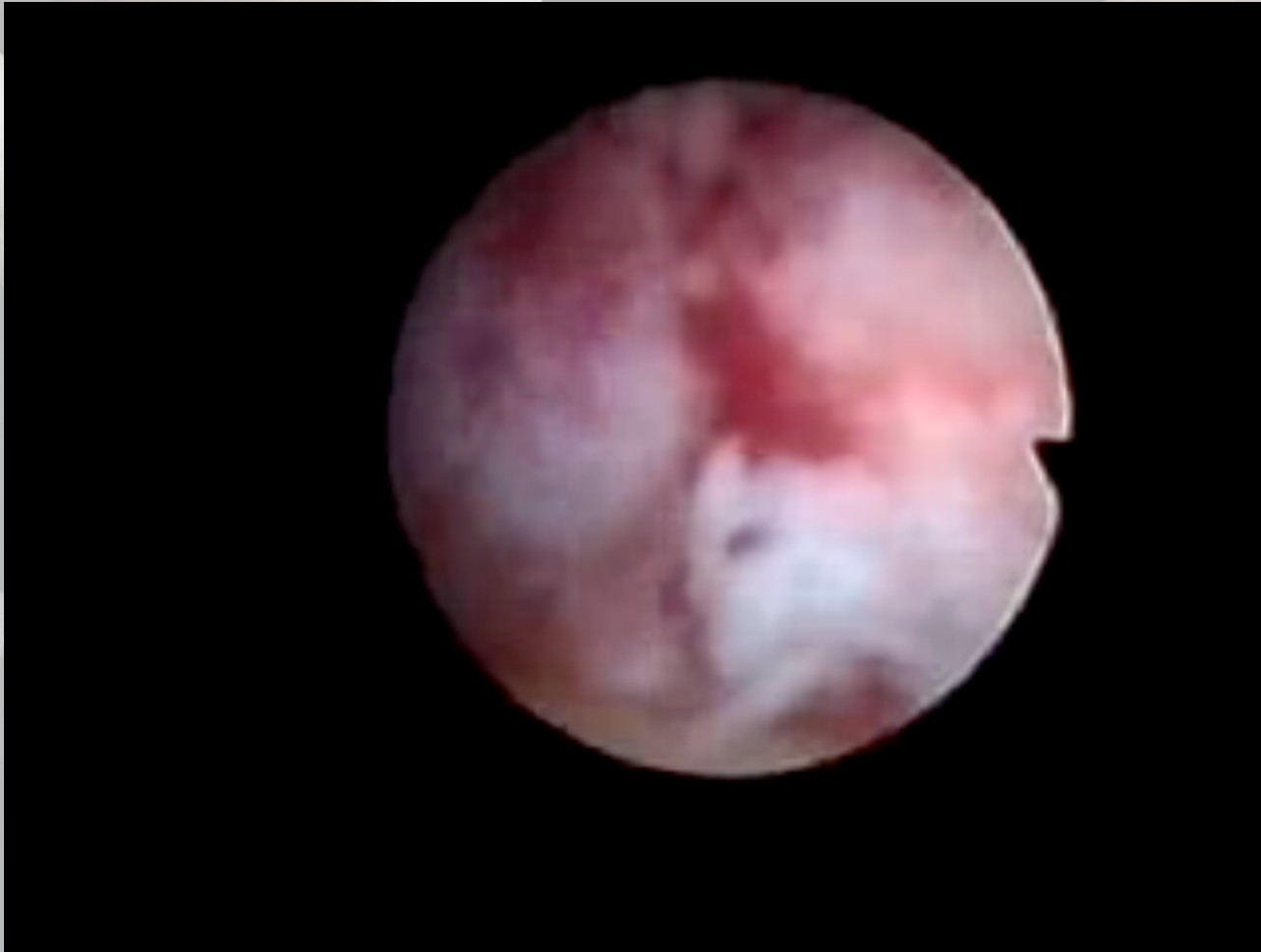

- There have been numerous recent publications regarding the role of ankle arthroscopy in the diagnosis and treatment of combined intra-articular fractures of the ankle.
- The author's experience is that it allows a more accurate pre-operative assessment of the articular surfaces, removal of chondral or osteochondral loose fragments and removal of clot and early arthrofibrotic tissue, producing faster rehabilitation and better outcomes. This is supported by Ono A et al (88) in July 2004 with a series of 105 ankles.
- Ankle arthroscopy can also be used to treat poor results following standard fixation techniques, treating previously undiagnosed osteochondral lesions and syndemotic injuries and arthrofibrosis (89).

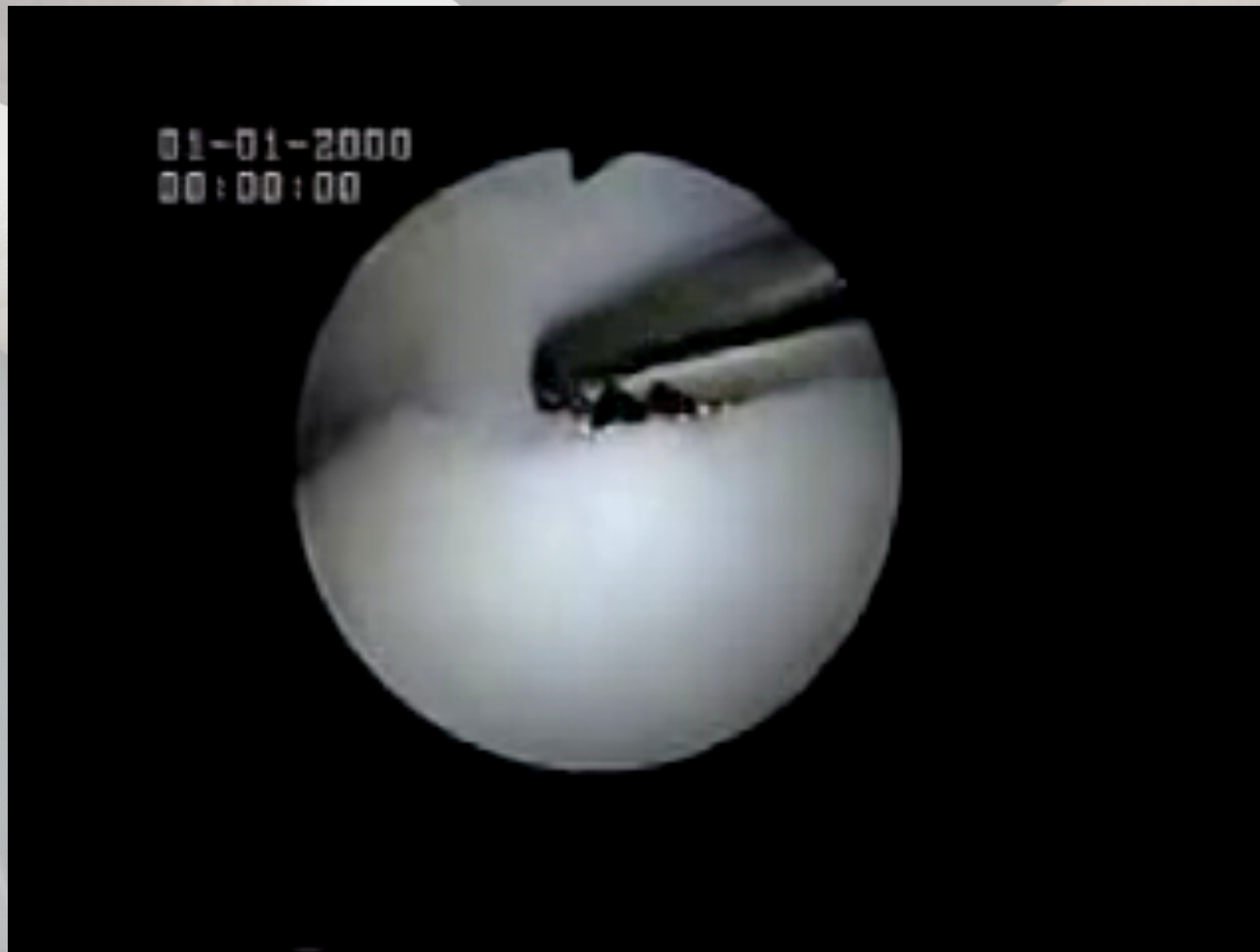Video: Meniscoid bands



Video: Synovial Disease



Video: Osteochondral Defects



www.ankle-arthroscopy.co.uk

Ankle Arthroscopy

[HOME](#) [PATIENTS' SITE](#) [SURGEONS' SITE](#) [VIDEOS](#) [ABOUT SIMON MOYES](#) [CONTACT](#) [LINKS](#)



Ankle Arthroscopy Website

Simon Moyes specialises in keyhole – or arthroscopic – surgery. This site is dedicated to conditions of the ankle joint that are treated by Simon. Patients can find all the information they need about some of the more common ankle problems, while surgeons and medical professionals can find an up-to-date medical resource for those involved in or studying ankle arthroscopy.

Quick Search

Go straight to the specific page you are looking for by using the drop down below:

Specific Condition

Search Site

Patients' Site

An outline of common ankle problems, with information about how the injury / ailment feels, what surgery is likely and the projected recovery time.

[Click here for the Patients' Site](#)

Surgeons' Site

An in-depth resource about all aspects of ankle arthroscopy for medical professionals. Contains highly-referenced documentation of the procedure, citing examples from the early history to current findings.

[Click here for the Surgeons' Site](#)

Simon Moyes | Medico-legal © Simon Moyes 2007 | [sitemap](#) | [disclaimer](#)

oscopy.co.uk